J Neurosurg Spine 2:243–248, 2005

Efficacy of percutaneous vertebroplasty combined with radiotherapy in osteolytic metastatic spinal tumors

JEE-SOO JANG, M.D., AND SANG-HO LEE, M.D.

Wooridul Spinal Hospital, Seoul, South Korea

Object. Vertebroplasty involves the percutaneous injection of polymethylmethacrylate into collapsed vertebral bodies due to hemangioma, osteoporosis, or malignant tumor. The purpose of this study was to evaluate the merits and efficacy of percutaneous vertebroplasty (PVP) combined with radiotherapy in treating patients with osteolytic metastatic spinal tumors (OMSTs).

Methods. Twenty-eight patients with OMSTs underwent PVP for the treatment of 72 vertebrae after administration of a local anesthetic or induction of general anesthesia for pain relief and spinal stabilization. Radiotherapy for suppressing tumor or inducing pain relief was performed immediately after PVP in 22 patients. Pain levels were assessed before and after the procedure by using a visual analog scale (VAS), and follow-up assessment was conducted at 1, 3, 6, and 9 months. On postoperative Day 3, marked-to-complete VAS score–based pain relief was achieved in 13 patients (48%) and moderate relief was demonstrated in 11 (41%). The mean VAS pain score was reduced from 8.2 to 3, and major complications were absent in all cases. Follow-up plain radiography was performed to assess vertebral column stability. Neither additional vertebral collapse in the treated vertebrae nor neurological deterioration was observed.

Conclusions. Percutaneous vertebroplasty is a minimally invasive procedure and, when combined with radiotherapy, seems to be effective in providing pain relief and stabilization in patients with OMSTs.

KEY WORDS • osteolytic metastatic spinal tumor • percutaneous vertebroplasty • polymethylmethacrylate • radiotherapy

PERCUTANEOUS vertebroplasty involves the injection of PMMA, under fluoroscopic guidance, into a vertebra to strengthen it and prevent further collapse. This procedure has been proposed for use in cases involving painful vertebral hemangiomas, spinal tumors, and osteoporotic compression fractures of the VBs.[1,3,4,6–9,11,13,14,19] The management of metastatic spinal tumors not associated with neurological deficit includes radiotherapy alone and a combination of surgery and radiotherapy for tumor suppression, pain reduction, and spinal stabilization. Surgical management, however, is often limited by a patient's poor general condition, the multifocal nature of the tumor, and the patient's short life expectancy. Furthermore, because spinal instability is not aided by the provision of radiation therapy,[17] this modality alone cannot provide stability or pain relief in the unstable spine.

The purpose of this study was to evaluate the merits and efficacy of PVP combined with radiotherapy in patients with OMSTs. The indications, technique, complications, and clinical results of our work are also described.

Clinical Material and Methods

Twenty-eight patients (17 women and 11 men, ranging in age from 40–72 years) with OMST underwent percutaneous injections of PMMA into 72 vertebrae. The primary tumor sites were lung, stomach, cervix, and breast (Table 1). All patients underwent plain radiography, magnetic resonance imaging, and bone scanning for evaluation of metastasis extension. Preoperative CT scanning was performed to assess the location and extent of the osteolytic lesion and the presence of cortical destruction. Segmental instability was defined as either movement-induced aggravation of pain or radiographically documented progressive collapse of VBs involved with the metastatic spinal tumor. The indication for PVP was an unstable or painful osteolytic metastatic tumor in the absence of neurological deficits (Fig. 1). The inclusion criteria for this study were vertebral collapse in patients with or without axial pain or painful vertebra in the absence of collapse (Fig. 1). We performed PVP at the level of VB collapse or at the affected level when an MR imaging signal change of the VB indicated that prevention of progressive vertebral collapse was necessary. If the patients suffered any neurological deficits due to the epidural compression of neural elements, PVP was not performed; however, we performed PVP even when the radiculopathy was caused by instability rather than the presence of a tumor mass. Many patients with metastatic spinal tumor were not suitable candidates for open surgery because of multilevel involvement, their poor general condition, or short life expectancy. Such patients are good candidates for PVP in lieu of open surgery. Conservative therapy including opiate analgesic agents, continuous epidural morphine injection, and, in some cases, radiotherapy had previously failed in all patients. Patients with myelopathy due to cord compression, severe coagulopathy, or systemic infection were excluded from this study. Neu-

Abbreviations used in this paper: AP = anteroposterior; CT = computerized tomography; OMST = osteolytic metastatic spinal tumor; PMMA = polymethylmethacrylate; PVP = percutaneous vertebroplasty; VAS = visual analog scale; VB = vertebral body.

TABLE 1

Summary of data obtained in 28 patients with OMSTs who underwent PVP and radiotherapy

Case No.	Age (yrs), Sex	Primary Cancer	VAS Score		PVP Levels	Indication for PVP	Follow-Up Period (mos)	Comment
			Preop	Postop				
1	54, F	RCC	9	2	L-1	pain & instability	7	dead
2	72, F	stomach	10	5	C-2	pain & instability	3	dead
3	34, F	breast	10	1	C3–5, T-3, T9–12	pain & instability	16	alive
4	61, M	metastasis of unknown origin	5	0	C-3	pain, instability, bone biopsy	10	dead
5	52, F	lung	5	0	T-7			dead, 3 PVPs at different times
			7	2	T-5	pain & instability	15	
			5	2	T-9			
6	40, F	breast	10	3	T-5	pain & instability	9	dead
7	63, F	stomach	10	4	C-6, T4–5, T-12	pain & instability	2	dead
8	68, F	lung	8	3	T-6, T-11, L-1	pain & instability	5	dead
9	41, M	hepatic	8	6	T-12, L-2	pain & instability	1	dead
10	53, F	thyroid	0*	0	T-11	instability	11	alive
11	48, F	multiple myeloma	8	4	T-12, L-2, L-4	pain & instability	2	dead
12	65, F	cervix	8	5	L-3			
			8	1	L-1, L-2, L-4, L-5	pain & instability	12	dead
13	72, F	cervix	9	3	L-1, L-5	pain & instability	13	dead
14	40, F	cervix	8	0	L-1	pain & instability	12	alive
15	60, M	multiple myeloma	8	8	T-6, T9–11, L-2	pain & instability	8	dead, pulmonary embolism
			8	6	L-1		8	
16	40, F	breast	9	2	C-7	pain & instability	13	alive
17	57, F	multiple myeloma	5	2	T-11, L1–2, L-4	pain & instability	8	dead, pulmonary embolism
18	60, F	multiple myeloma	5	1	T-10, T-12, L-1, L-2, L-4, L-5	pain & instability	7	alive, pulmonary embolism
19	59, F	rectal	8	6	C-6, T-3	pain & instability	4	dead
20	62, M	mesothelioma	8	4	T9–10	pain & instability	6	dead
21	63, M	prostate	7	2	T11–L2	pain & instability	6	dead
22	54, M	stomach	10	3	L-3	pain & instability	6	dead
23	55, M	multiple myeloma	8	3	L1–3	pain & instability	9	dead
24	60, M	multiple myeloma	9	2	L-2	pain & instability	5	alive
25	71, M	lung	10	4	C-3	pain & instability	3	dead
26	31, M	lung	8	1	T-7, L-4	pain & instability	8	dead
27	52, F	thyroid	10	3	T-12	pain & instability	9	alive
28	65, F	lung	8	2	L1–2	pain & instability	6	dead

* The patient in this case did not have pain. The PVP was performed only to stabilize the VB.

rological examinations in all patients were performed prior to treatment, and no patient suffered neurological dysfunction prior to or after treatment.

In 27 of the 28 patients, PVP was performed both for VB stabilization and pain relief, whereas in one case it was performed primarily for stabilization. Preoperatively, 24 patients received oral morphine sulfate and three underwent epidural injections of morphine for pain control; however, their pain remained intolerable despite these measures. Following the procedure, opiate analgesic therapy and epidural morphine injections were tapered and then discontinued. Nonopiate analgesic agents were used for postoperative pain. In cases involving intensifying pain, analgesic medications were progressively changed to opiate analgesic agents. The cause of the vertebral lesion was metastasis in 22 patients and myeloma in six. In 17 patients, multiple vertebrae were treated, either simultaneously or at different times. Of the total 72 treated vertebrae, nine were cervical, 30 were thoracic, and 33 were lumbar. Most patients were permitted to ambulate using a semirigid lumbar brace or collar neck brace on postoperative Day 1, and flexion, extension, and rotation spinal motion limitation was required.

Percutaneous vertebroplasty was performed under fluoroscopic guidance in all patients after induction of general endotracheal anesthesia (six patients) or administration of a local anesthetic (22 patients). The use of the C-arm or fluoroscopy allowed AP and lateral viewing without the need to move the patient. For cervical lesions, an anterolateral approach was used with patients in the supine position. After making a small skin incision following administration of a local anesthetic, a 10-gauge, 11-cm-long needle with blunt stylet was directed toward the VB through the cleavage plane between the trachea and carotid artery sheath. When the tip came in contact with the VB, the blunt stylet was changed to a sharp stylet to penetrate the cortical bone.

An extrapedicular approach at the thoracic levels and a transpedicular approach at the lumbar levels were usually undertaken using a 10-gauge, 11-cm-long needle. The position of the needle was checked frequently in both planes, in the AP and lateral views, to prevent the needle tip from penetrating the spinal canal or an adjacent vertebra. Tissue samples for histopathological examination were extracted through the needle, if needed. The PMMA cement (Howmedica, Rutherford, NJ) was mixed with 2 g barium sulfate powder, and the cement mixture was allowed to polymerize until it achieved the creamlike consistency necessary for controlled injection. The main difficulty at this point was the selection of the cement's appropriate viscosity. Lower-viscosity cement tended to leak into the spinal canal, whereas higher-viscosity cement made effective injection into the body difficult. Thus, barium sulfate powder was added to increase the PMMA opacity. Prior to injection, PMMA was loaded into several 1-ml syringes. In cases requiring more excessive force, a stylet was introduced

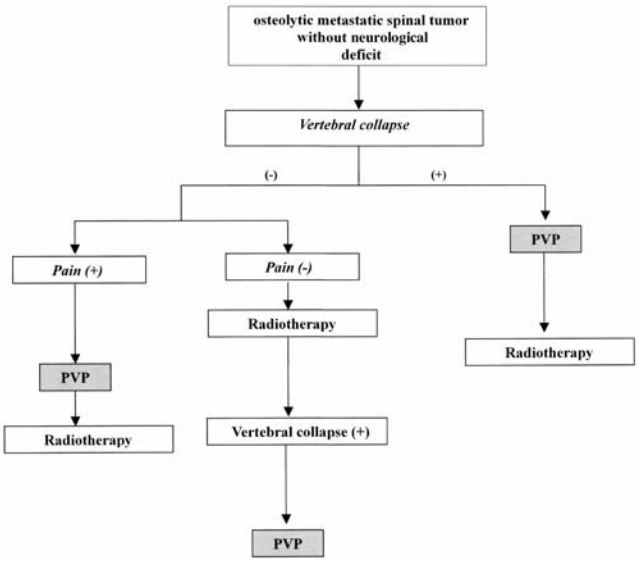

FIG. 1. Diagram for selection of the preferred therapeutic approach in patients with osteolytic metastatic spinal tumors without neurological deficit. The PVP is an important treatment modality for pain relief and stabilization. + = present; − = absent.

into the needle to facilitate the injection. The injection was ceased immediately when continuous fluoroscopic monitoring indicated that the PMMA had reached the posterior wall of the VB or demonstrated extravertebral venous filling. The needle was not removed until the PMMA had hardened to prevent leakage through the hole. If the PMMA had not crossed the midline, an identical procedure was performed contralaterally. After the procedure, neurological (motor and sensory) examinations were performed for early detection of PMMA leak–induced neural compression.

Plain AP and lateral radiography and CT scanning were performed to assess the location and potential leakage of PMMA. Most patients were permitted to be ambulatory 1 day posttreatment. Radiation therapy commenced immediately after the completion of procedures for tumor suppression and pain relief in 22 patients. The most common fractionation schedule was 300-cGy boluses to a total dosage of 3000 cGy. In six patients, PVP was performed to treat progressive collapse of VBs or because radiotherapy failed to provide pain relief. In Case 21, the patient suffered severe back pain despite undergoing lumbar radiotherapy. Magnetic resonance imaging revealed widespread cancerous spinal involvement secondary to prostate cancer, and CT scanning demonstrated posterior cortical destruction of L-2 (Fig. 2). We performed PVP at the level of vertebral collapse caused by tumor involvement (Fig. 2). Postoperatively, pain relief was dramatic, and the patient could ambulate without assistive devices on postoperative Day 1. Plain radiographic examinations 1, 3, 6, and 9 months postoperatively were performed to assess vertebral column stability. Pain was evaluated using a VAS in which scores ranged from 0 to 10 (preoperatively, immediately postoperatively and at follow up at 1, 3, 6, and 9 months after treatment); neurological examinations were conducted at the same time points by the spine surgeon member of the treatment team.

The median follow-up period was 7.7 months (range 1–16 months). The numbers of patients available for evaluation at each follow-up interval were as follows: 26 at 1 month, 21 at 3 months, 14 at 6 months, and seven at 9 months. Twenty-one patients died during the follow-up period.

Results

The mean amount of PMMA injected per VB was 5 ml (range 3–11 ml). Fifty-six VBs were treated via a single unilateral approach because the PMMA flowed across the midline to fill adequately both vertebral hemispheres, whereas 16 VBs required bilateral injections.

Partial or complete pain relief was obtained within 3 days in 24 (89%) of the 27 patients postoperatively. Marked-to-complete pain relief, defined as a reduction of the VAS pain score by more than 5 points, was achieved in 13 patients (48%) and moderate pain relief (reduction of pain score by 5–3 points) was observed in another 11 (41%). In three patients pain relief was not significant. The level of pain did not worsen in any case. The mean VAS pain score was reduced from 8.2 to 3 by Day 3 postoperatively. After the procedure, five patients who had been nonambulatory because of their pain severity were able to walk. In one patient (Case 5), we performed a three-level PVP at different times because VB collapse developed anew during the follow-up course.

Preoperative CT scanning was performed to assess the location and extent of the osteolytic lesion and the presence of cortical destruction in all cases. Of the total 72 treated levels, CT scanning revealed posterior cortical wall destruction at 53 levels (73%). At the level of posterior cortical destruction, the possibility of PMMA epidural leakage was reduced because we created high-viscosity PMMA and added barium sulfate powder to increase the cement's opacity; as always, careful fluoroscopic monitoring was continuous.

In Case 26, the patient was bedridden because of severe neck pain. On neurological examination, no neurological deficit was observed. Radiography and MR imaging demonstrated C-3 VB collapse and spinal cord compression caused by a metastatic lung tumor. Open surgery was not indicated because of the patient's poor general condition, multiorgan involvement of the tumor, and his short life expectancy. In such an unstable state, neurological deterioration caused by cord compression could have occurred at any time. Therefore, we decided to perform PVP despite the danger of neurological deterioration. The procedure was performed at the level of the collapsed vertebra, and the patient thereafter underwent radiotherapy at the PVP-treated level (Fig. 3). Postoperatively, the pain was relieved and the patient experienced no neurological deficits. He was able to sit up while wearing a neck collar brace.

One month after vertebroplasty, one patient had died (the pain score was unchanged from initial postoperative score). Five patients missed their 3-month follow-up examinations; however, due to aggravation of their primary tumors pain scores were higher at the 6- and 9-month follow up compared with the initial postoperative scores (Fig. 4 *upper*). The scope of pain evaluation after vertebroplasty, however, was limited during the follow-up period because of the multiple origins of the cancer pain. The mean opiate analgesic dose was also increased during the follow-up

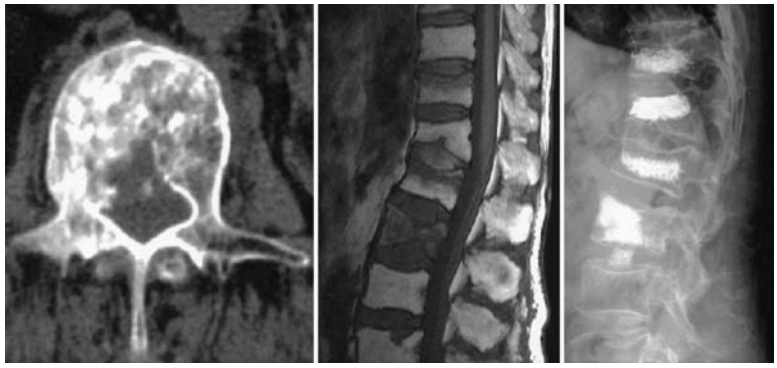

FIG. 2. Case 21. The patient experienced severe back pain despite undergoing thoracolumbar-region radiation therapy. *Left:* Axial CT scan revealing posterior cortical destruction of L-2. *Center:* Sagittal MR image demonstrating widespread spinal involvement at T-11, T-12, L-1, and L-2 from prostate cancer. *Right:* We performed PVP at the tumor-involved vertebrae.

period (Fig. 4 *lower*). Neither additional vertebral collapse of the treated VBs nor neurological deterioration was observed during the follow-up period. No patient required other spinal surgeries for disease progression.

Postoperative CT scanning revealed minor extra-VB leakage of PMMA in 52 of the 72 levels: in the spinal canal at 12 levels, the neural foramen at two, the adjacent discs at 17, the paravertebral tissues at 18, and the veins at 15. Intradiscal leakage of PMMA was associated with cortical fracture or osteolysis of the vertebral endplate. These leaks produced no clinical symptoms.

Pulmonary embolism secondary to the PVP was detected on chest radiography performed in three patients after the procedure. Two patients experienced mild dyspnea and chest discomfort and one was asymptomatic. Ventilation perfusion scanning was performed to detect the presence of any perfusion defects, none being found in these three cases. The symptoms of dyspnea and chest discomfort in two patients subsided after supplemental O_2 inhalational and anticoagulant therapy.

Illustrative Case

Case 1

This 54-year-old woman was referred to our hospital; she was bedridden because of progressive back pain and pain radiating to the left inguinal region. She rated her pain as a VAS score of 9. She had undergone surgery for renal cell carcinoma 4 years previously. Her back and radiating pain had begun to develop 4 months before referral, and its severity had worsened significantly prior to admission. At presentation she was nonambulatory because of the pain, and she experienced dyspnea that was caused by pleural effusion secondary to pulmonary metastasis. No neurological symptoms were present. Preoperative plain thoracic radiography, MR imaging, and CT scanning revealed an osteolytic compression fracture of L-1 without evidence of dural compression. Bone scanning revealed multiple bone metastases. Although an anterior approach was indicated for stabilization, this approach was inadvisable because of the patient's poor general condition. Therefore, after administration of a local anesthetic, the patient underwent PVP, radiation therapy, and she was ambulatory 1 day postoperatively. Her VAS pain score improved from 9 to 2 (Fig. 5).

Discussion

The spine is a frequent site for metastases and multiple myeloma. Therapeutic management of this disease depends on the disease, survival period, extent of the spine affected, neurological signs, and general condition of the patient. Palliative treatment is generally prescribed in patients with metastatic spinal lesions in an attempt to improve the quality of the patient's remaining life. The maintenance of spinal stability, reduction of pain, and prevention of neurological deterioration can affect a patient's quality of life. Surgical treatment and radiation therapy are commonly used for spinal metastases; however, surgery is limited by the multifocal nature of the disease, the short life expectancy, and the poor general condition of the patient. Radiation therapy also has limitations when it is undertaken to maintain of stability and control of the pain. In cases of multiple myeloma, chemotherapy may result in an increased risk of vertebral collapse and consequently of neural compression. Therefore, a stabilization procedure is needed when the lesion threatens spinal stability. In this study, segmental instability was assumed to be present when the clinical syndrome was characterized by the aggravation of pain by movement in the absence of neural enchroachment, progressive collapse of VBs, or localized kyphosis on imaging study.

Weill, et al.,[19] reported that 24 (73%) of 33 patients with metastatic lesions experienced clear improvement in pain levels, and Cotton, et al.,[4] indicated that 22 (59%) of 37 patients experienced marked pain relief. In our series, 24 patients (89%) experienced partial or complete pain relief. The mechanism of the analgesic effect is not clearly understood. The analgesic effect of vertebroplasty may be due to vertebral column stabilization and PMMA's destruction of the nerve terminals through its heat and cytotoxic effect.[5,6,10,13,19] Polymethylmethacrylate is toxic to cells when it is not completely polymerized.[5,10]

The appropriate volume of PMMA that is most effective for pain relief and stabilization varies among reports. Tohmeh, et al.,[18] found that 6 ml of cement in unilateral or 5 ml in bilateral injections resulted in similar stiffness values and significantly increased strength relative to the prefracture state; they also reported that there was no significant biomechanical difference between uni- and bipedicular verte-



FIG. 3. Case 25. This 72-year-old man with previously diagnosed lung cancer presented with severe neck pain. *Left:* Sagittal MR image demonstrating a C-3 metastatic tumor. *Center:* Plain lateral x-ray film demonstrating a severe C-3 osteolytic lesion. *Right:* Lateral fluoroscopic image obtained during the procedure, demonstrating final PMMA casting.

broplasties when the PMMA was placed in the vertebral center or crossed the midline. Cotton, et al.,[4] however, demonstrated that no direct relationship existed between pain relief and the ratio of the lesion filled. Liebschner and coworkers[12] also demonstrated that only a small amount of bone cement (15% of the cavity filled) was needed to restore stiffness to damaged levels and that asymmetrical distribution with large-volume fills can promote single-sided load transfer and, thus, toggle. They concluded that the symmetrical distribution of PMMA was more important for stabilization than the injected volume. Therefore, excessive volumes of cement are not needed for stabilization and should be avoided to reduce extravertebral leakage.

The extrapedicular approach is more effective than the transpedicular in the thoracic spine. The needle can be introduced at a greater transverse angle, which allows the needle tip to be located in the center of the VB without violating the spinal canal. Therefore, it was possible to place the PMMA in the vertebral center or across the midline by using a unilateral injection. In our study, the mean amount of PMMA injected per VB was 5 ml (range 3–11 ml). Fifty-seven VBs were treated with a single unilateral approach as PMMA flowed across the midline to fill adequately both vertebral hemispheres, while 13 VBs received bilateral punctures.

Immediate radiation therapy is needed after vertebroplasty for tumor suppression and pain relief. Moreover, the clinical use of irradiation against neoplastic disease in bone is not affected by the presence of PMMA, nor is the PMMA affected by the level of the dosage of radiation in clinical use.[15] More than half of those patients with pain experience pain relief following radiotherapy alone;[2] however, this modality alone does not provide stability or pain relief in the patient whose spine is unstable. In this study, PVP was performed to treat progressive VB collapse or, in six patients, lack of pain relief after having undergone radiation therapy.

The main technical complications are related to PMMA leakages into the spinal canal, neural foramen, or perivertebral vein. Leakages into the spinal canal in 12 of the 72 levels, possibly due to leakages into the epidural vein, produced no symptoms of cord compression. Although posterior cortical destruction is not an absolute contraindication to vertebroplasty,[19] careful and continuous fluoroscopic monitoring during PMMA injection should be performed to decrease leakage into the spinal canal. Foraminal PMMA leakage has been shown to lead to nerve compression or thermal injury.[4]

Cement leakage into a vein could lead to pulmonary embolism of PMMA, with possibly disastrous conse-

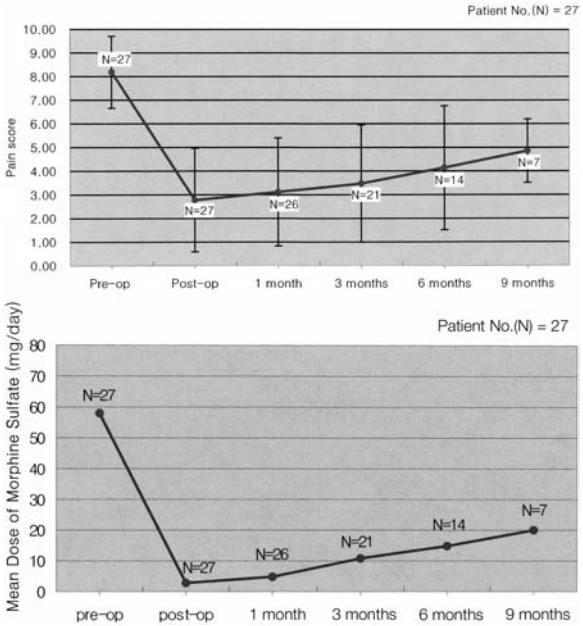

FIG. 4. *Upper:* The mean pain score was reduced from 8.2 to 3 on postoperative Day 3. Five patients missed their 3-month follow-up examinations and the pain scores at 6- and 9-month follow-up visits were higher than the initial postoperative pain score due to aggravation of the patients' primary tumors. *Lower:* Opiate analgesic agents were tapered and discontinued after the procedure. In case of intensifying pain, the mean dose of opiate analgesic agents was progressively increased during the follow-up period.

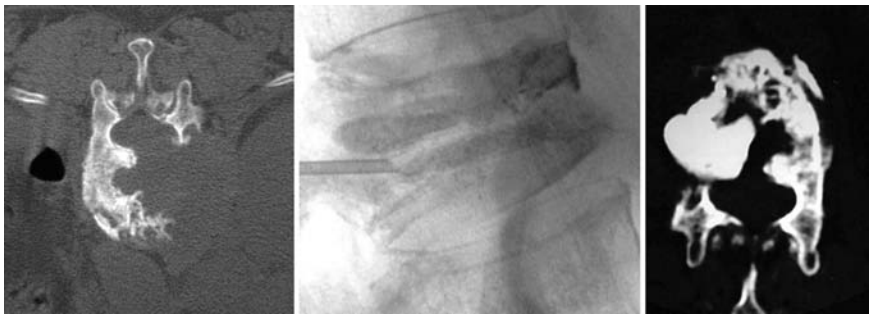

FIG. 5. Case 1. A 54-year-old woman who had suffered renal cancer presented with severe back and radiating leg pain. *Left:* Axial CT scan revealing cortical destruction and an osteolytic lesion of the L-1 VB. *Center:* Lateral fluoroscopic image obtained during procedure, demonstrating final PMMA casting. *Right:* Axial CT scan obtained after PVP, revealing PMMA in the VB.

quences. Its major complication, pulmonary infarction, involves the necrosis of lung parenchyma, resulting from interference with the blood supply.[16] In our study, a pulmonary PMMA embolism was detected in three patients on postoperative chest radiography, but it was not associated with significant complications. Despite the high incidence of extravertebra leakage, few clinical complications occurred; however, the potential complications including cord compression, radiculopathy, pulmonary embolism, intercostal neuralgia, and infection always required consideration. Therefore, this procedure requires a surgical team specializing in emergency decompressive surgery.

Conclusions

Percutaneous vertebroplasty, a salvage and minimally invasive procedure that can provide pain relief and stability, can be successfully performed in combination with radiotherapy for the treatment of OMST.

References

1. Bascoulergue Y, Duquesnel J, Leclercq R: Percutaneous injection of methylmethacrylate in the vertebral body for the treatment of various disease: percutaneous vertebroplasty. **Radiology 169:**372, 1988 (Abstract)
2. Byrne TN: Spinal cord compression from epidural metastases. **N Eng J Med 327:**614–619, 1992
3. Cotten A, Boutry N, Cortet B, Assaker R, Demondion X, Leblond D, et al: Percutaneous vertebroplasty: state of the art. **Radiographics 18:**311–323, 1998
4. Cotten A, Dewatre F, Cortet B, Assaker R, Leblind D, Duquesnoy B, et al: Percutaneous vertebroplasty for osteolytic metastases and myeloma: effects of the percentage of lesion filling and the leakage of methyl methacrylate at clinical follow-up. **Radiology 200:**525–530, 1996
5. Dahl OE, Garvik LJ, Lyberg T: Toxic effects of methylmethacrylate monomer on leukocytes and endothelial cells in vitro. **Acta Orthop Scand 65:**147–153, 1994
6. Debussche-Depriester C, Deramond H, Fardellone P: Percutaneous vertebroplasty with acrylic cement in the treatment of osteoporotic vertebral crush fracture syndrome. **Neuroradiology 33:**149–152, 1991
7. Deramond H, Darrason R, Galibert P: Percutaneous vertebroplasty with acryl cement in the treatment of aggressive spinal angiomas. **Rachis 1:**143–153, 1989
8. Deramond H, Galibert P, Debussche C: Percutaneous vertebroplasty with methylmethacrylate: technique, method, result. **Radiology 77:**352, 1990 (Abstract)
9. Gangi A, Kastler BA, Dietemann JL: Percutaneous vertebroplasty guided by a combination of CT and fluoroscopy. **AJNR 15:**83–86, 1994
10. Jefferiss CD, Lee AJ, Ling RS: Thermal aspects of self-curing polymethylmethacrylate. **J Bone Joint Surg Br 57:**511–518, 1975
11. Jensen ME, Evans AJ, Mathis JM, Kallmes DF, Cloft HJ, Dion JE: Percutaneous polymethylmethacrylate vertebroplasty in the treatment of osteoporotilc vertebral body compression fractures: technical aspects. **AJNR 18:**1897–1904, 1997
12. Liebschner MA, Rosenberg WS, Keaveny TM: Effects of bone cement volume and distribution on vertebral stiffness after vertebroplasty. **Spine 26:**1547–1554, 2001
13. Kaemmerlen P, Thiesse P, Jonas P: Percutaneous injection of orthopedic cement in metastatic vertebral lesions. **N Eng J Med 321:**121, 1989 (Letter)
14. McAllister VL, Kendall BE, Bull JW: Symptomatic vertebral haemangiomas. **Brain 98:**71–80, 1975
15. Murray JA, Bruels MC, Lindberg RD: Irradiation of polymethylmethacrylate. In vitro gamma radiation effect.**J Bone Joint Surg Am 56:**311–312, 1974
16. Padovani B, Kasriel O, Brunner P, Peretti-Viton P: Pulmonary embolism caused by acrylic cement: a rare complication of percutaneous vertebroplasty. **AJNR 20:**375–377, 1999
17. Sundaresan N, Galicich JH, Lane JM, Bains MS, McCormack P: Treatment of neoplastic epidural cord compression by vertebral body resection and stabilization. **J Neurosurg 63:**676–684, 1985
18. Tohmeh AG, Mathis JM, Fenton DC, Levine AM, Belkoff SM: Biomechanical efficacy of unipedicular versus bipedicular vertebroplasty for the management of osteoporotic compression fractures. **Spine 24:**1772–1776, 1999
19. Weill A, Chiras J, Simon JM, Rose M, Sola-Martinez T, Enkaoua E: Spinal metastases: indications for and results of percutaneous injection of acrylic surgical cement. **Radiology 199:** 241–247, 1996

Manuscript received February 10, 2004.
Accepted in final form September 23, 2004.
This paper was presented in poster format at the 16th annual meeting (2001) of the North American Spine Society.

Address reprint requests to: Jee-Soo Jang, M.D., Wooridul Spinal Hospital, 47-4, Chungdam-Dong, Kangnam-Gu, Seoul, Korea, 135-100. email: spinejjs@yahoo.co.kr.