online © ML Comm
www.jkns.or.kr 10.3340/jkns.2010.48.6.496
Print ISSN 2005-3711 On-line ISSN 1598-7876
J Korean Neurosurg Soc 48 : 496-500, 2010
Copyright © 2010 The Korean Neurosurgical Society

Clinical Article

Clinical and Radiological Outcomes of Unilateral Facetectomy and Interbody Fusion Using Expandable Cages for Lumbosacral Foraminal Stenosis

Jin Hoon Park, M.D., Chae Wan Bae, M.D., Sang Ryong Jeon, M.D., Seung Chul Rhim, M.D., Chang Jin Kim, M.D., Sung Woo Roh, M.D., Ph.D.
Department of Neurosurgery, Asan Medical Center, University of Ulsan College of Medicine, Seoul, Korea

Objective : Surgical treatment of lumbosacral foraminal stenosis requires an understanding of the anatomy of the lumbosacral area in individual patients. Unilateral facetectomy has been used to completely decompress entrapment of the L5 nerve root, followed in some patients by posterior lumbar interbody fusion (PLIF) with stand-alone cages

Methods : We assessed 34 patients with lumbosacral foraminal stenosis who were treated with unilateral facetectomy and PLIF using stand-alone cages in our center from January 2004 to September 2007. All the patients underwent follow-up X-rays, including a dynamic view, at 3, 6, 12, 24 months, and computed tomography (CT) at 24 months postoperatively. Clinical outcomes were analyzed with the mean numeric rating scale (NRS), Oswestry Disability Index (ODI) and Odom's criteria. Radiological outcomes were assessed with change of disc height, defined as the average of anterior, middle, and posterior height in plain X-rays. In addition, lumbosacral fusion was also assessed with dynamic X-ray and CT.

Results : Mean NRS score, which was 9.29 prior to surgery, was 1.5 at 18 months after surgery. The decrease in NRS was statistically significant. Excellent and good groups with regard to Odom's criteria were 31 cases (91%) and three cases (9%) were fair. Pre-operative mean ODI of 28.4 decreased to 14.2 at post-operative 24 months. In 30 patients, a bone bridge on CT scan was identified. The change in disc height was 8.11 mm, 10.02 mm and 9.63 mm preoperatively, immediate postoperatively and at 24 months after surgery, respectively.

Conclusion : In the treatment of lumbosacral foraminal stenosis, unilateral facetectomy and interbody fusion using expandable stand-alone cages may be considered as one treatment option to maintain post-operative alignment and to obtain satisfactory clinical outcomes.

KEY WORDS : Expandable cage · Foraminal stenosis · Lumbosacral spine.

INTRODUCTION

Surgical treatment of lumbosacral foraminal stenosis requires understanding of individual anatomy of this area. The anatomical uniqueness of this area has given us the use of several different treatment options. Since the concept of L5 nerve root entrapment was first introduced in 1925, various surgical methods have been attempted and good outcomes have been reported[9,12,13].

Foraminal root entrapment has been observed in 8-11% of patients who have degenerative lumbar disease. Similar incidence of L5 root entrapment by this pathology has been reported and associated with clinical pain or claudication. Complete facetectomy in the lumbosacral region allows full decompression of the L5 nerve root, avoiding unintentional neural injury. Although lumbosacral extraforaminal disc herniation can be treated via the lateral approach, foraminal stenosis caused by degenerative disc bulging offers a greater obstacle in decompressing the nerve root avoiding facectectomy[3,4].

The authors retrospectively reviewed the patients who had lumbosacral foraminal stenosis and treated by unilateral facetectomy, followed by posterior lumbar interbody fusion (PLIF) using stand-alone cages. Although, there are many different opinions in the manner of fusion after facetectomy, our goals were the complete decompression of nerve root, removal of offending lesion and elevation of disc height because persistent axial loading of the disc space after decompression may contribute to insufficiency.

• Received : July 12, 2010 • Revised : September 24, 2010
• Accepted : December 28, 2010
• Address for reprints : Sung Woo Roh , M.D., Ph.D.
Department of Neurosurgery, Asan Medical Center, University of Ulsan College of Medicine, Pungnap-2 dong, Songpa-gu, Seoul 138-736, Korea
Tel : +82-2-3010-3550, Fax : +82-2-476-6738
E-mail : swroh@amc.seoul.kr

MATERIALS AND METHODS

We assessed 34 patients with lumbosacral foraminal stenosis who were treated in our center from January 2004 to September 2007. Mean follow up period was 48 months and minimally 24 months follow up was done. All patients presented with unilateral radiating leg pain, with or without back pain, and all had symptoms unresponsive to a minimum of 3 months conservative treatment. Pre-operative magnetic resonance (MR) imaging showed unilateral L5-S1 foraminal and lateral recess stenosis in all patients.

Selection of patient included lumbosacral foraminal stenosis on MR image with correlating L5 radiculopathy and selective L5 root block of some patients who had vague symptom. However, patients with significant instability on dynamic X-ray, L5-S1 spondylolisthesis of more than grade I and pure extraforaminal disc were excluded (Fig. 1). The patients consisted of 9 men and 25 women, and mean age was 57.6 years (range, 37-76 years). Their pre-operative mean lumbosacral disc height was 8.11 mm, ranging from 6.45 to 10.31 mm, indicating severe narrowing of the disc space.

All of these patients underwent subtotal laminectomy and unilateral L5-S1 facetectomy. After identifying L5 and S1 nerve roots, discectomy was done in the usual manner. Then, bone chips obtained *in-vivo* were inserted into the disc space and two proper sized cages filled with remaining local bone were inserted and expanded under fluoroscopy guidance (Fig. 2). On the second day after operation, patients were allowed to stand by themselves. They were advised to keep lumbosacral orthosis for 2 months after operation.

Patient medical records were reviewed until 24 months following surgery, with additional information obtained from telephone interviews. All patients underwent follow-up X-rays, including a dynamic view, at 3, 6, 12, 24 months, and computed tomography (CT) at 24 months postoperatively.

Clinical outcomes were analyzed with the mean numeric rating scale (NRS), Oswestry Disability Index (ODI) and Odom's criteria. Changes in disc height defined as the average of anterior, middle and posterior height on plain radiograph were assessed. All measurements were performed pre- and post-operatively. Lumbosacral fusion was also assessed with dynamic X-ray and CT. Fusion criteria included stability on dynamic view (angular difference < 1°), absence of halo, and formation of a contiguous bony bridge.

Statistical comparisons utilized the Wilcoxon signed rank

Table 1. Patient demographics and clinical characteristics at baseline

	PLIF (n = 34)
Mean age (range), years	57.6 (37-76)
Sex (M : F)	9 : 25
Facetectomy (left : right)	26 : 8
Smoker : Non-smoker	6 : 28
Follow up period (mean), months	24-70 (48)

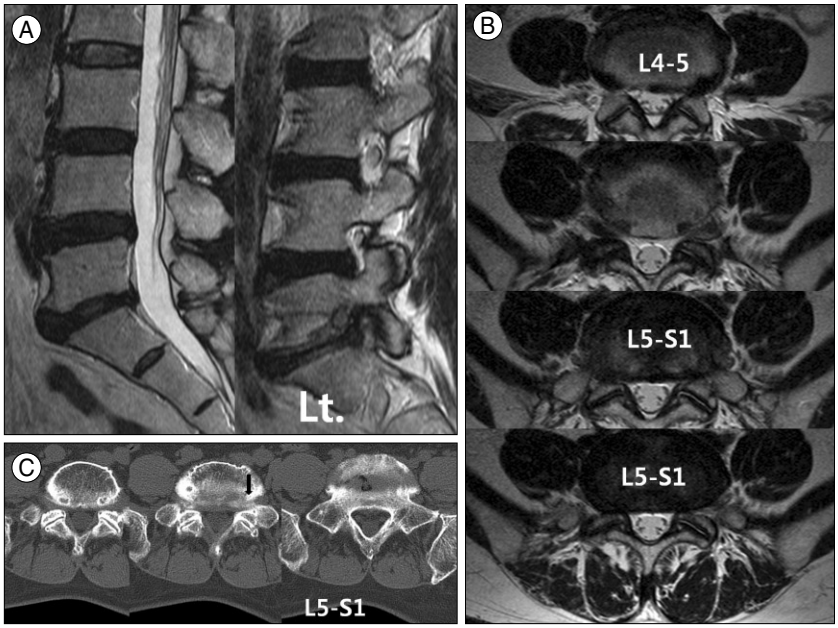

Fig.1. Pre-operative MRI. A : T2-weighted sagittal MR image, showing left L5-S1 foraminal stenosis and disc height narrowing. B : T2-weighted axial MR image, showing a left L5-S1 neural foramen stenosis (middle and exit zone), suspected of being an offending lesion. C : Pre-operative CT image showing left L5-S1 foraminal narrowing and bony spur (arrow).

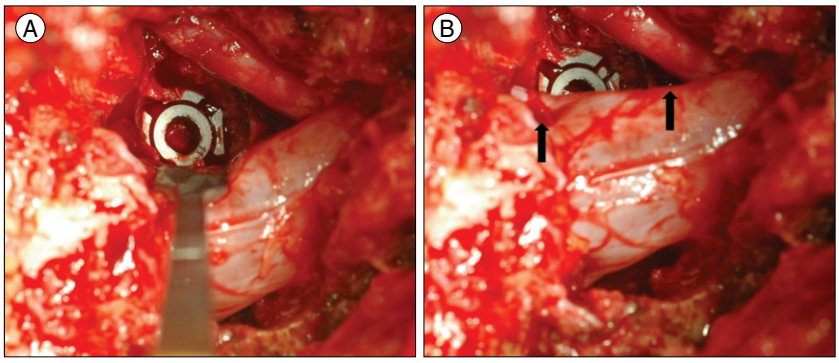

Fig. 2. Operative findings. A : Unilateral laminectomy and facetectomy to decompress the L5 nerve root along the foramen. Following left unilateral facetectomy, an interbody fusion cage is observed in the disc space. B : Decompression of the L5 and S1 roots (arrow).

test and the Mann-Whitney U test.

RESULTS

Mean operation time was 137 minutes (122-197 minutes) and estimated blood loss was 345 mL. Length of hospital stay was 5.3 days (4-8 days).

Mean NRS score, which was 9.29 prior to surgery, was 1.5 at 18 months after surgery. The decrease of NRS showed statistical significance. Excellent and good groups regarding to Odom's criteria were 31 cases (91%) and three cases (9%) were fair. Three cases of the 34 patients complained of recurrent pain (NRS > 5). However in three patients, immediate relief of leg pain was seen postoperatively but subsequent back pain and leg pain relapsed after six months. Preoperative mean ODI was 28.4 changed to 14.2 twenty-four months postoperatively (Table 2).

Bone bridging on CT scans were identified in 30 patients and lumbosacral instability defined as movement over 1 degree on dynamic radiograph was not found in any patient. The actual fusion rate satisfying the above criteria was 88%. There was no case of instability in any patient who could not achieve fusion. The significant relationship between the clinical outcome and fusion was not found in our results (Fig. 3).

Disc height changed from 8.11 mm preoperatively to 10.02 mm immediate postoperatively and to 9.63 mm at 24 months following surgery. The height increase of clinically successful group was statistically significant, but that of clinical failure group was not significant (Table 3).

Cage subsidences (the difference between immediate post-operation and post-operative 12 months > 0.5 mm) were noted in ten patients. Two of these patients were rated as fair and one other was rated as good according to Odom's criteria.

Complication related to surgery, such as infection, dura tear, and hematoma, was not found, although post-operative paresthesia of the leg were seen in five patients and the duration was a maximum of six days.

Table 2. Clinical results of PLIF with standalone cages for lumbosacral foraminal stenosis

Clinical outcomes	Results
Mean operation time	137 minutes
Estimated blood loss	345 mL
Length of hospital stay	5.3 days
Odom's criteria at post-operative 24 months	Exellent : 10
	Good : 21
	Fair : 3
	Poor : 0
NRS of Leg pain (pre-operation → post-operation 24 month)	9.29 → 1.5
ODI (pre-operation → post-operation 24 month)	28.4 → 14.2

Table 3. Clinical and radiological correlation of the lumbosacral PLIF surgery

PLIF (n = 34)			
Fusion	Fusion	Non-fusion	
Whole (n = 34)	30	4	88.2%
Clinical success group (n = 31)	29	2	93.5%
Clinical failure group (n = 3)	1	2	33.3%
Disc height (mm)	Pre Op.	Post Op. (24 Months)	*p* value
Whole (n = 34)	8.11 (6.45-10.97)	9.63 (9.07-11.67)	0.002
Clinical success group (n = 31)	7.85 (6.45-10.45)	9.46 (9.07-11.45)	0.002
Clinical failure group (n = 3)	10.81 (9.50-10.97)	11.35 (10.39-11.67)	0.750

Wilcoxon signed rank test. Clinical Success Group : Excellent and Good in Odom's criteria. Clinical Failure Group : Fair and Poor in Odom's criteria

DISCUSSION

Foraminal stenosis has been estimated to occur in 8-11% of patients with degenerative disc disease. At our medical center, 11% of patients with overall degenerative lumbosacral disease were diagnosed with foraminal steno-

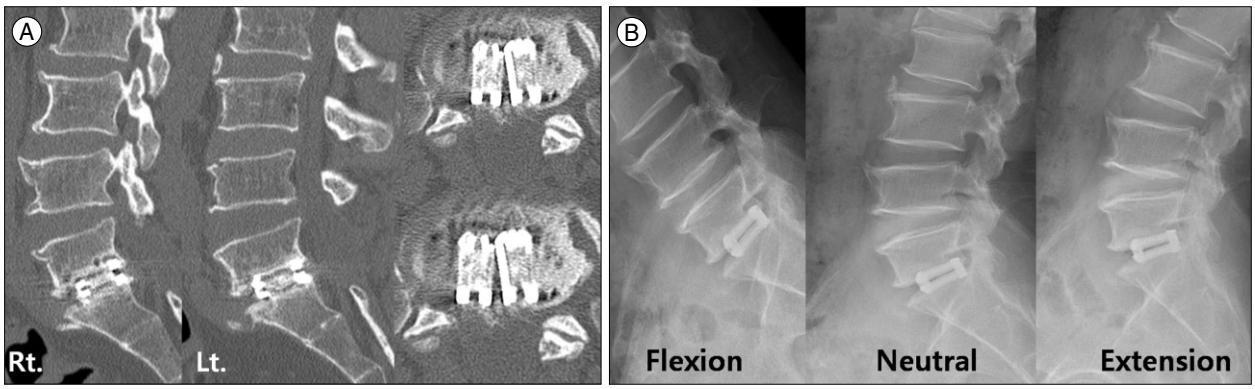

Fig. 3. Post-operative image. A : Post-operative 24-month-CT image showing a bony bridge indicative of fusion. B : Dynamic series showing no instability.

sis. Surgery is difficult because of the narrow surgical corridors, although many surgical alternatives are available. A deep anatomical understanding of the lumbosacral area can help to determine the most appropriate surgical method for treatment of lumbosacral foraminal stenosis.

In this anatomic area, as the isthmus of the lamina becomes much wider at lower levels, the nerve roots must travel a longer distance. Therefore, the L5 nerve root is particularly vulnerable to compression in this tract[3,4,11,14]. In addition, many studies have reported that this area is biomechanically stable and iliolumbar ligament plays an important role in the stability[1,8,15].The iliolumbar ligament extends from the transverse processes of L4 and L5 to the anteromedial side of the iliac crest. The function of the iliolumbar ligament is involvement in all directional motion. If this ligament were absent, the range of motion in the lumbosacral junction would increase.

Foraminal stenosis can be classified according to its location, such as at the entrance, middle, or exit zone. If root compression occurs exclusively at the entrance or exit zone, decompression via a medial or lateral approach may be sufficient[12]. However, collapsed and bulging discs which occur frequently, compress the L5 nerve root passage throughout the middle zone. Therefore, it may be insufficient to decompress the neural foramen from the medial or lateral direction.

Decreased height of the lumbosacral disc and bulging are also associated with an increased risk for root compression in the middle zone. A normal structure, such as a transverse process including the accessory process, the ala of the sacrum, and the facet joint in the lumbosacral area, may be involved with L5 root compression. The L5 accessory process is larger and the distance between the transverse process and the facet joint smaller than in the upper vertebrae[11]. Therefore, a degenerative disc with bulging and facet joint and ligament flavum hypertrophy and bony spur can be easily offending lesions of this area[7,10]. Therefore, we assumed that the an appropriate treatment of this disease may consist of full decompression of the L5 nerve root from proximal to distal via facetectomy and elevation of the disc height by interbody fusion.

We used expandable, stand-alone cages for interbody fusion; these achieved 88% fusion in our patients. This finding agrees with the results of trials showing that stand-alone cages contribute to the maintenance of stability[2,6], with one study reporting an overall 92.3% fusion rate with expandable, stand-alone cages[5]. Laminectomy and interbody fusion with expandable, stand-alone cages can decrease the morbidity related to screw fixation, such as excessive muscle retraction, screw breakage and pullout, and upper facet joint violation, as seen in our study. In addition, our procedures are economical compared with additive pedicle screw fixation and is accompanied by satisfactory fusion results. We also agree with the opinion that the screw fixation is more helpful in obtaining stability. However, the lumbosacral joint has a relatively smaller range of motion and iliolumbar ligament, which supports the L5 vertebra to the ilium, gives this area stability. Our results which indicated that there was not instability in patients who could not achieve fusion, also showed the stability of the lumbosacral joint. These factors led us to perform unilateral facetectomy and PLIF using stand-alone cages. Another factor which made us confident in the stability was the structure of the cage which could expand and anchor at the end-plate.

The success of the fusions did not correlate with the clinical outcomes, as another study had previously reported[12].

We also observed that the height of the disc space had increased at the last follow-up, thus indicating that the middle and exit zones of the foramen occupied a larger space after surgery than was the case preoperatively. If cage subsidence occurs, the space would gradually decrease. In fact, our results in the post-operative 24th month showed that a decrease of disc height, thus indicating that subsidence had occurred. However, among the ten of our patients in whom cage subsidence occurred, only two experienced recurrent pain. Because of the small number of our cases, this finding could not explain the significant correlation between the clinical outcome and the cage subsidence.

Using this surgical method, we obtained satisfactory clinical and radiological results, with a reduction in pre-operative, radiating leg pain. In our study, the removal of the offending lesion via facetectomy seems to be related with a successful clinical outcome.

CONCLUSION

In the treatment of lumbosacral foraminal stenosis, unilateral facetectomy and interbody fusion using expandable stand-alone cages may be considered a treatment option in order to maintain post-operative alignment and obtain satisfactory clinical outcomes.

Radiological fusion was 88% with fusion criteria, but there was no instability in the any patient who did not achieve fusion. The disc height changed from 8.11 mm preoperatively to 10.02 mm immediate postoperatively and 9.63 mm at 24 months after surgery. The height increase of the clinical success group was statistically significant and that of the clinical failure group was not significant. Cage subsidence occurred, but without a clinical correlation.

References

1. Aihara T, Takahashi K, Yamagata M, Moriya H, Tamaki T : Biomechanical functions of the iliolumbar ligament in l5 spondylolysis. J

Orthop Sci 5 : 238-242, 2000
2. Chen SH, Tai CL, Lin CY, Hsieh PH, Chen WP : Biomechanical comparison of a new stand-alone anterior lumbar interbody fusion cage with established fixation techniques - a three-dimensional finite element analysis. **BMC Musculoskelet Disord 9** : 88, 2008
3. Epstein NE : Different surgical approaches to far lateral lumbar disc herniations. **J Spinal Disord 8** : 383-394, 1995
4. Epstein NE : Foraminal and far lateral lumbar disc herniations : Surgical alternatives and outcome measures. **Spinal Cord 40** : 491-500, 2002
5. Kim JW, Park HC, Yoon SH, Oh SH, Roh SW, Rim DC, et al. : A multi-center clinical study of posterior lumbar interbody fusion with the expandable stand-alone cage (tyche(r) cage) for degenerative lumbar spinal disorders. **J Korean Neurosurg Soc 42** : 251-257, 2007
6. Krijnen MR, Mensch D, van Dieen JH, Wuisman PI, Smit TH : Primary spinal segment stability with a stand-alone cage: In vitro evaluation of a successful goat model. **Acta Orthop 77** : 454-461, 2006
7. Lee CK, Rauschning W, Glenn W: Lateral lumbar spinal canal stenosis : Classification, pathologic anatomy and surgical decompression. **Spine (Phila Pa 1976) 13** : 313-320, 1988
8. Leong JC, Luk KD, Chow DH, Woo CW : The biomechanical functions of the iliolumbar ligament in maintaining stability of the lumbosacral junction. **Spine (Phila Pa 1976) 12** : 669-674, 1987
9. Park YK, Kim JH, Chung HS, Suh JK : Microsurgical midline approach for the decompression of extraforaminal stenosis in L5-S1. **J Neurosurg 98** : 264-270, 2003
10. Porter RW, Hibbert C, Evans C : The natural history of root entrapment syndrome. **Spine (Phila Pa 1976) 9** : 418-421, 1984
11. Reulen HJ, Muller A, Ebeling U : Microsurgical anatomy of the lateral approach to extraforaminal lumbar disc herniations. **Neurosurgery 39** : 345-350; discussion 350-351, 1996
12. Sengupta DK, Herkowitz HN : Lumbar spinal stenosis. Treatment strategies and indications for surgery. **Orthop Clin North Am 34** : 281-295, 2003
13. Song J, Lee JB, Suh JK : Clinicopathological considerations in patients with lumbosacral extraforaminal stenosis. **J Clin Neurosci 16** : 650-654, 2009
14. Wiltse LL, Guyer RD, Spencer CW, Glenn WV, Porter IS : Alar transverse process impingement of the l5 spinal nerve : the far-out syndrome. **Spine 9** : 31-41, 1984
15. Yamamoto I, Panjabi MM, Oxland TR, Crisco JJ : The role of the iliolumbar ligament in the lumbosacral junction. **Spine 15** : 1138-1141, 1990